

POTENTIAL OF SONOGRAPHY IN DIAGNOSIS OF TONGUE TUMORS

N. A. Maksimova, M. A. Engibarjan, M. G. Ilchenko[✉], L. G. Akopian, V. V. Gurnak,
A. S. Egorova, M. A. Cherkas

National Medical Research Centre for Oncology, Rostov-on-Don, Russian Federation

✉ maria_ilchenko80@mail.ru

ABSTRACT

Purpose of the study. An analysis of sonography potential in the primary diagnosis and clinical staging of tongue cancer.

Patients and methods. The study included 18 patients aged 40–70 years with tongue tumors. The majority accounted males – 14 (77.7 %). Women were represented by 4 (22.2 %) examinees. Ultrasound examinations were performed using expert-class ultrasound systems with broadband linear multifrequency transducers.

Transoral examination with linear transducers required tumor location in the anterior and lateral parts of the oral tongue.

During ultrasound examinations we evaluated: tumor shape, tumor invasion depth; tumor sizes – width and thickness; tumor echogenicity and structure; tumor vascularization in Doppler modes.

The results were compared with the data of histological examination.

Results. Transoral ultrasound examination of patients with tongue cancer allows clear visualization of the tumor and assessment of its spread.

The study showed that the round shape of tongue tumors prevailed in 13 (72.2 %) patients, the tumor echo structure in 10 (55.5 %) was heterogeneous, the contours were even and clear in the majority of patients – 13 (72.2 %), all tumors showed a reduced acoustic density, the depth of invasion ranged from 2 to 6 mm in 8 (44.4 %) patients and exceeded 6 mm in 6 (33.3 %) patients, which corresponded to stages III and IV of the diseases. Doppler ultrasonography recorded intense intratumoral blood flow in 100 % of cases. In 8 (44.4 %) cases, metastatic lesions of the cervical lymph nodes were observed.

Conclusion. Transoral ultrasound diagnosis of tongue cancer is a highly informative, safe and modern method providing surgeons with information that helps in choosing the scope of surgical treatment and in determining the disease prognosis at the preoperative stage. The accuracy of the method was 87 %, the sensitivity was 85 %, and the specificity was 86.2 %.

Keywords:

tongue cancer, ultrasound examination, transoral access

For correspondence:

Maria G. Ilchenko – Cand. Sci. (Med.), scientific fellow at the Tumor Diagnostics Department National Medical Research Centre for Oncology, Rostov-on-Don, Russian Federation.

Address: 63 14 line str., Rostov-on-Don 344037, Russian Federation

E-mail: maria_ilchenko80@mail.ru

ORCID: <https://orcid.org/0000-0002-9126-0646>

SPIN: 2856-7946, AuthorID: 734046

ResearcherID: AAT-9807-2020

Funding: this work was not funded.

Conflict of interest: authors report no conflict of interest.

For citation:

Maksimova N. A., Engibarjan M. A., Ilchenko M. G., Akopian L. G., Gurnak V. V., Egorova A. S., Cherkas M. A. Potential of sonography in diagnosis of tongue tumors. South Russian Journal of Cancer. 2022; 3(1): 40-45. (In Russ.). <https://doi.org/10.37748/2686-9039-2022-3-1-5>.

The article was submitted 08.10.2021; approved after reviewing 07.02.2022; accepted for publication 14.03.2022.

© Maksimova N. A., Engibarjan M. A., Ilchenko M. G., Akopian L. G., Gurnak V. V., Egorova A. S., Cherkas M. A., 2022

ВОЗМОЖНОСТИ СОНОГРАФИИ В ДИАГНОСТИКЕ ОПУХОЛЕЙ ЯЗЫКА

Н. А. Максимова, М. А. Енгибарян, М. Г. Ильченко[✉], Л. Г. Акопян, В. В. Гурнак, А. С. Егорова, М. А. Черкес

НМИЦ онкологии, г. Ростов-на-Дону, Российская Федерация

✉ maria_ilchenko80@mail.ru

РЕЗЮМЕ

Цель исследования. Изучить возможности ультразвукового исследования в первичной диагностике и клиническом стадировании рака языка.

Пациенты и методы. В исследование вошло 18 больных с опухолью языка в возрасте от 40 до 70 лет. Большинство пациентов – мужчины – 14 (77,7 %). Женщины были представлены 4 (22,2 %) наблюдениями. Ультразвуковые исследования выполнялись на аппаратах экспертного класса, широкополосными линейными мультисекторными датчиками. Необходимым условием для трансорального исследования являлось расположение опухоли в передних и боковых отделах подвижной части языка.

При УЗИ первичного очага мы оценивали: форму, размеры, глубину инвазии опухоли; экзогенность и структуру образования, васкуляризацию в режимах доплерографии.

Полученные результаты сравнивались с данными гистологического исследования.

Результаты. При обследовании больных раком языка с применением трансоральной методики ультразвукового исследования удается четко визуализировать опухоль, определить распространенность процесса.

В результате исследования превалировала округлая форма опухолей языка у 13 (72,2 %), пациентов, эхо-структура новообразования у 10 (55,5 %) была неоднородная, контуры у большинства ровные, четкие – 13 (72,2 %), все новообразования имели пониженную акустическую плотность, глубина инвазии у 8 (44,4 %) пациентов составляла от 2 до 6 мм и у 6 (33,3 %) больше 6 мм, что соответствует III, IV стадиям заболевания. В 100 % наблюдений при доплерографии регистрировался интенсивный внутриопухолевый кровоток. В 8 (44,4 %) случаях наблюдалось метастатическое поражение шейных лимфоузлов.

Заключение. УЗ-диагностика трансоральным доступом рака языка – высокоинформативный, безопасный, современный метод, дающий информацию врачам-хирургам, помогающую в выборе объема хирургического лечения и в определении на дооперационном этапе прогноза заболевания. Точность метода составила 87 %, чувствительность – 85 %, специфичность – 86,2 %.

Ключевые слова:

рак языка, ультразвуковое исследование, трансоральный доступ

Для корреспонденции:

Ильченко Мария Геннадьевна – к.м.н., научный сотрудник отдела диагностики опухолей ФГБУ «НМИЦ онкологии» Минздрава России, г. Ростов-на-Дону, Российская Федерация.

Адрес: 344037, г. Ростов-на-Дону, ул. 14 линия, д. 63, Россия

E-mail: maria_ilchenko80@mail.ru

ORCID: <https://orcid.org/0000-0002-9126-0646>

SPIN: 2856-7946, AuthorID: 734046

ResearcherID: AAT-9807-2020

Финансирование: финансирование данной работы не проводилось.

Конфликт интересов: авторы заявляют об отсутствии конфликта интересов.

Для цитирования:

Максимова Н. А., Енгибарян М. А., Ильченко М. Г., Акопян Л. Г., Гурнак В. В., Егорова А. С., Черкес М. А. Возможности сонографии в диагностике опухолей языка. Южно-Российский онкологический журнал. 2022; 3(1): 40-45. <https://doi.org/10.37748/2686-9039-2022-3-1-5>.

Статья поступила в редакцию 08.10.2021; одобрена после рецензирования 07.02.2022; принята к публикации 14.03.2022.

INTRODUCTION

Tongue cancer accounts for 65 % of the incidence of malignant neoplasms of the oral cavity and develops from elements of the squamous epithelium. Men get sick 5–7 times more often than women, as a rule, in adulthood, after 50 years [1; 2]. The incidence of malignant neoplasms of the tongue is steadily increasing [3]. Despite the fact that tongue cancer is a localization available for examination, up to 80 % of patients do not consult a doctor for a long time and at the time of initial treatment, the stage of the disease is III–IV. All this confirms the relevance of the topic of diagnosis and treatment of tongue cancer.

Systematic interaction of the tongue mucosa with various chewing mixtures, cigarette smoke, strong alcohol, as well as chronic diseases of the tongue, such as ulcers, infection in the oral cavity, traumatization, erythroplakia, leukoplakia, are etiological factors of the development of tongue cancer [1–5].

In 65 % of cases, the tumor is located on the lateral surfaces of the tongue and in 90–95 % of cases it is squamous cell carcinoma. According to the form, there are: papillary, ulcerative, infiltrative and infiltrative-ulcerative forms of tongue cancer.

By development and growth: exophytic tumor protruding into the oral cavity and endophytic, diffuse tumor that grows into the deep layers of the tongue, oral cavity.

Metastatic lesion of the cervical lymph nodes in cancer of the tongue occurs in 40–80 %. Hematogenous metastases are rare, they can affect the liver, lungs, skeletal bones, and brain [6].

Accurate information about the extent of the tumor process at the preoperative stage allows you to choose the necessary treatment strategy [7–8].

Ultrasound examination (ultrasound) is a non-invasive, easy-to-use method for detecting changes in the free part of the tongue and lymph nodes of the neck [9; 10]. However, the use of ultrasound in the primary diagnosis of tongue cancer has not been sufficiently studied and requires special consideration of all possible aspects.

The purpose of the study: to study the possibilities of ultrasound examination in the primary diagnosis and clinical staging of tongue cancer.

PATIENTS AND METHODS

The study included ultrasound data of 18 patients, aged 40 to 70 years, with malignant tumor processes

of the tongue. By gender, the patients were distributed as follows: men – 14 (77.7 %), women – 4 (22.2 %).

Ultrasound was performed on the devices "IU 22 PHILIPS", broadband multi-frequency linear sensors, 5–17 MHz.

To assess the shape, size, echogenicity, echo structure, depth of invasion this is the distance from the surface of the neoplasm to the lower border of the tumor, deep into the muscles of the tongue, vascularization in the modes of DH, EDC of the primary tumor located in the lateral and anterior sections of the movable part of the tongue, we performed ultrasound with transoral access.

The obtained results of the depth of invasion of the neoplasm were compared with the data of histological examination.

RESEARCH RESULTS AND DISCUSSION

In the study of patients with tongue cancer using ultrasound transoral access, it is possible to visualize the tumor and determine the prevalence of the process. Table 1 presents the main sonographic criteria for tumors of the tongue of patients included in our study.

As a result of the study, the shape of the tumors of the tongue prevailed rounded in 13 (72.2 %), the oblong form was registered in 5 (27.7 %) patients, the echo structure in 10 (55.5 %) was heterogeneous, the contours of the majority were smooth, clear – 13 (72.2 %), all neoplasms had a reduced acoustic density, the depth of invasion was in 8 (44.4 %) from 2 to 6 mm and in 6 (33.3 %) more than 6 mm, which corresponds to the III, IV stages of the disease and confirms the literature data on late the appeal of patients. Intense intra-tumor blood flow was recorded in DH. Metastatic lesion of cervical lymph nodes was observed in 8 (44.4 %) cases.

The accuracy of the method was 87 %, sensitivity 85 %, specificity 86.2 %.

A clinical case.

Patient M., born in 1960, applied for an appointment with complaints about the presence of a tumor on the tongue, considers herself ill for three months when she discovered a nodular formation on the left side of her neck. Not treated.

When examined, a dense, limited movable node up to 25 mm is determined in the carotid triangle of the neck on the left. On the lateral surface of the

free part of the tongue on the left, a tumor infiltrate measuring 45 × 25 mm is determined.

A CT scan of the brain and soft tissues of the neck was performed on the patient – no pathological changes in the brain substance were detected. Infiltrative lesion of the tongue, mts in the left side of the neck.

In the projection of the lateral surface of the free part of the tongue on the left, a hypoechoic formation, irregular shape, uneven contours, fuzzy, 1.3 × 3.0 cm in size, the depth of invasion is 13 mm (Fig. 1), with DH – hyperintensive intranodular blood flow (Fig. 2).

The cervical lymph nodes on the right are not enlarged, on the left in the upper third 1.3–2.3 cm (Fig. 3).

A biopsy of the tongue tumor was performed – layers of squamous cell carcinoma with a tendency to keratinization. Minor leukocyte infiltration. A puncture biopsy of the specified lymph node was performed. The cytogram is characteristic of metastasis of squamous cell carcinoma with keratinization.

Based on the clinical diagnostic study, the diagnosis was made: tongue cancer with metastases to the lymph nodes of the neck on the left St III (T3N1M0), cl. gr. 2.

The patient underwent surgical treatment in the volume of combined resection of the floor of the oral cavity with microsurgical plastic surgery, cervical lymphadenectomy on the left. G.A: Metastasis of

Table 1. Sonographic criteria for tumors of the tongue

Diagnostic criteria		Abs. numb.	%
Shape	Rounded	10	55.5
	Oblong	4	22.2
	Irregular	4	22.2
Size	Up to 20 cm	7	38.9
	20–40 cm	8	44.4
	Above 40 cm	3	16.7
Contours	Smooth/distinct	13	72.2
	Smooth/not distinct	-	-
	Rough/distinct	3	16.7
	Rough/not distinct	2	11.1
Echogenisity	Homogenous	6	33.3
	Non homogenous	12	66.7
Acoustic density	Isoechgenic	-	-
	Hypoechogenic	18	100
	Anechogenic	-	-
Invasion depth	Up to 5 mm	4	22.2
	4–10 mm	8	44.4
	Above 10 mm	6	33.3
L.n. lesion	Present	8	44.4
L.n. lesion	Absent	10	55.5
Vascularization	Central	5	27.8
	Peripheral	0	0
	Mixed	13	72.2
Blood flow intensity	Isointensive	5	27.8
	Hypeintensive	10	55.5
	Hypointensive	3	16.7

squamous cell carcinoma with keratinization; squamous cell carcinoma with keratinization, infiltrative growth. Invasion of the deep muscle layer. Invasion – 10 mm. The next stage, after topometric preparation on a Simens Somatom computed tomograph (Effective dose per study 4.5 mSv) using radiopaque labels and dosimetric planning, a course of remote gamma therapy was conducted on the bed of the removed tumor and a lymphocollector, irradiation was carried out on a TERATRON device, 2.4 G, 5 fractions per week, 17 fractions, SOD 40.8 G (42izoGr). Final diagnosis. Cancer of the tongue with metastases in the l/nodes of the neck on the left, still, pT3N1M0, condition after surgical treatment, radiation treatment SOD 42 Gr, cl. gr. 2

CONCLUSION

Based on the conducted studies, it is safe to say that determining the depth of tumor invasion with transoral ultrasound of the tongue, as well as examining the soft tissues of the neck to identify metastatic regional lymph nodes helps to establish the stage of the disease. Thus, ultrasound diagnosis of tongue cancer is a highly informative, safe, modern method that provides information to surgeons, helps in choosing the scope of surgical treatment and at the preoperative stage to determine the prognosis of the disease. The accuracy of the method was 87 %, sensitivity 85 %, specificity 86.2 %.

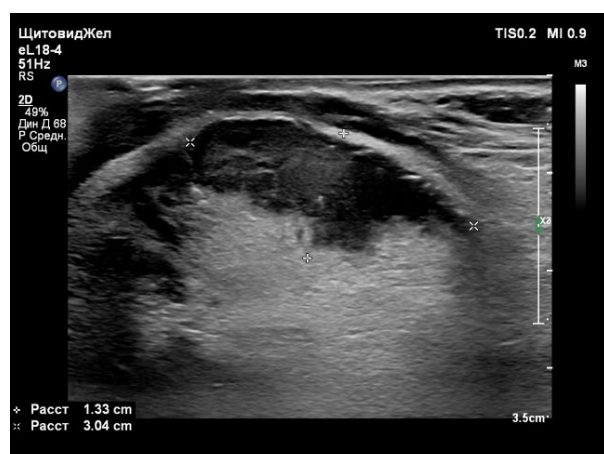

Fig. 1. B-mode ultrasound image of a tongue tumor: hypoechoic neoplasm, irregular shape, uneven, indistinct contours, heterogeneous echostructure, 1.3 × 3.0 cm in size.

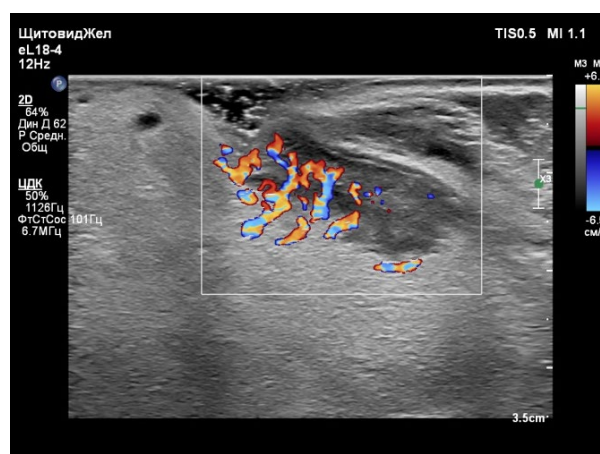


Fig. 2. Color Doppler ultrasound image of a tongue tumor: hyperintense intra- and perinodular blood flow.

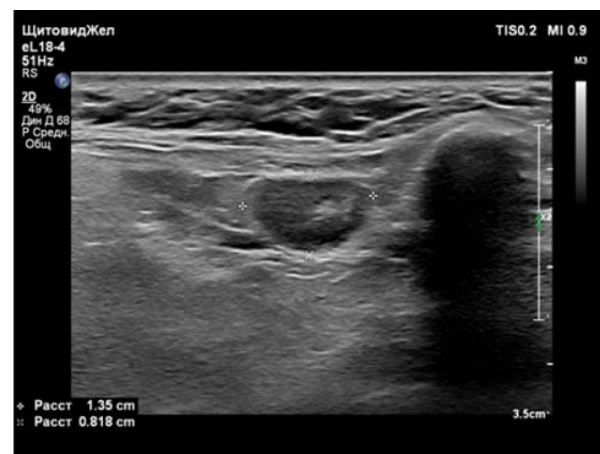
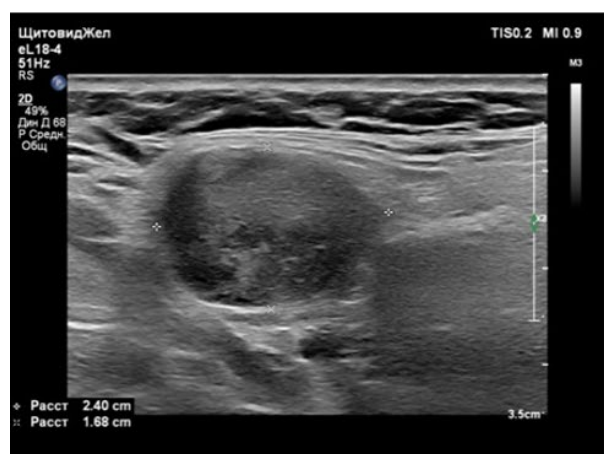


Fig. 3. B-mode ultrasound image of lateral surfaces of the neck – hypoechoic lymph nodes, heterogeneous echostructure, 1.3–2.4 cm in size.

Reference

1. Alieva SB, Alymov YuV, Kropotov MA. Cancer of the oral mucosa. Oncology. Clinical recommendations. Ed. by M. I. Davydov. Moscow: Publishing Group of the Russian Research Center, 2015, 27–37 p. (In Russ.).
2. Kit OI, Duritskiy MN, Shelyakina TV, Engibaryan MA. Some characteristics of detection of oncological diseases of head and neck organs in cancer institution and institution of general health services. Modern Problems of Science and Education. 2015;(4):451. (In Russ.).
3. Malignant neoplasms in Russia in 2017 (morbidity and mortality). Edited by A.D. Kaprin, V.V. Starinsky, G.V. Petrova. Moscow: P. A. Hertsen Moscow Oncology Research Institute – Branch of the National Medical Research Radiological Centre, 2018, 250 p. (In Russ.).
4. Gelfand IM, Romanov IS, Udintsov DB. Treatment policy for localized oral cancer. Head and Neck Tumors (HNT). 2016;6(1):43–45. (In Russ.). <https://doi.org/10.17650/2222-1468-2016-6-1-43-45>
5. Bolotina LV, Vladimirova LYu, Dengina NV, Novik AV, Romanov IS. Practical recommendations for the treatment of malignant tumors of the head and neck. Malignant tumors: Practical Recommendations RUSSCO #3s2. 2018;8(3S2):71–82. (In Russ.). <https://doi.org/10.18027/2224-5057-2018-8-3s2-71-82>
6. Paches AI. Tumors of the head and neck. 5th ed., add. and reprint. Moscow: Practical Medicine, 2013, 480 p. (In Russ.).
7. Stepanov SO, Mitina LA, Ratushnaya VV, Dolgacheva DV, Soloviev VA, Kolesnikova EV. Ultrasound diagnostics of tumors of the tongue. Oncosurgery. 2013;5(4):4–7. Available at: <http://oncosurgery.oncology.ru/archive/2013/04/1.htm>. Accessed: 02.04.2021.
8. Allahverdieva GF, Sinyukova GT, Kropotov MA, Mudunov AM, Yakovleva LP, Saprina OA, et al. Ultrasound diagnosis of tongue cancer. Determination of the depth of tumor invasion. Malignant Tumors. 2015;(4S2(16)):49–52. (In Russ.). <https://doi.org/10.18027/2224-5057-2015-4s2-49-52>
9. Soloviev VA, Reshetov IV, Mitina LA, Stepanov SO, Kazakevich VI, Shcherbina VG, Borodina NB. Ultrasound examination in cases of tongue and floor of the mouth cancer. Medical Visualization. 2015;1:26–31. (In Russ.).
10. Soloviev VA, Ratushnaya VV, Mitina LA, Stepanov SO. Capabilities of ultrasound diagnosis of early tumors of the tongue. SonoAce Ultrasound. 2021;33:58–62. (In Russ.).

Information about authors:

Natalya A. Maksimova – Dr. Sci. (Med.), professor, head of the radioisotope laboratory with the ultrasound diagnostics group National Medical Research Centre for Oncology, Rostov-on-Don, Russian Federation. ORCID: <https://orcid.org/0000-0002-0400-0302>, SPIN: 1785-9046, AuthorID: 375005, ResearcherID: AAT-9775-2020, Scopus Author ID: 57211495326

Marina A. Engibaryan – Dr. Sci. (Med.), head of the Department of Head and Neck Tumors National Medical Research Centre for Oncology, Rostov-on-Don, Russian Federation. ORCID: <https://orcid.org/0000-0001-7293-2358>, SPIN: 1764-0276, AuthorID: 318503, Scopus Author ID: 57046075800

Maria G. Ilchenko ✉ – Cand. Sci. (Med.), scientific fellow at the Tumor Diagnostics Department National Medical Research Centre for Oncology, Rostov-on-Don, Russian Federation. ORCID: <https://orcid.org/0000-0002-9126-0646>, SPIN: 2856-7946, AuthorID: 734046, ResearcherID: AAT-9807-2020

Liudmila G. Akopian – radiologist, Radioisotope Laboratory with Ultrasonic Diagnostics Group, National Medical Research Centre for Oncology, Rostov-on-Don, Russian Federation. ORCID: <https://orcid.org/0000-0003-1013-6553>, SPIN: 4348-1471, AuthorID: 735227

Viktor V. Gurnak – Cand. Sci. (Med.), radiologist, Radioisotope Laboratory with Ultrasonic Diagnostics Group, National Medical Research Centre for Oncology, Rostov-on-Don, Russian Federation. ORCID: <https://orcid.org/0000-0002-1958-1197>, SPIN: 9581-8030, AuthorID: 794885

Anna S. Egorova – sonologist, Radioisotope Laboratory with Ultrasonic Diagnostics Group, National Medical Research Centre for Oncology, Rostov-on-Don, Russian Federation. ORCID: <https://orcid.org/0000-0002-7139-1956>, SPIN: 6204-5624, AuthorID: 799247

Maria A. Cherkes – Cand. Med. Sc., oncologist, Consulting and Diagnostic Department, National Medical Research Centre for Oncology, Rostov-on-Don, Russian Federation. ORCID: <https://orcid.org/0000-0003-4576-2829>, SPIN: 8534-3323, AuthorID: 799197

Contribution of the authors:

Maksimova N. A. – concept, scientific guidance, final conclusions;
Engibaryan M. A. – concept, scientific editing of the manuscript;
Ilchenko M. G. – manuscript writing, material collection, processing and analysis;
Akopian L. G. – material collection and processing, data interpretation;
Gurnak V. V. – material collection and processing, text revision;
Egorova A. S. – material collection, preparation of figures;
Cherkes M. A. – material collection and processing.