

EXPERIENCE IN SURGICAL TREATMENT OF VERTEBRAL METASTATIC TUMORS OF CRANIOVERTEBRAL LOCALIZATION

O. I. Kit¹, D. E. Zakondyrin^{2✉}, E. E. Rostorguev¹, V. E. Rostorguev³, A. A. Maslov³

1. National Medical Research Centre for Oncology, Rostov-on-Don, Russian Federation

2. Moscow State Medical and Dental University named after A. I. Evdokimov, Moscow, Russian Federation

3. Rostov State Medical University, Rostov-on-Don, Russian Federation

✉ russiandoctor@mail.ru

ABSTRACT

Purpose of the study. Elaboration of a surgical technique to manage patients with metastatic lesions of the craniovertebral region.

Patients and methods. The study included 7 patients with metastatic lesions of the craniovertebral region, who've been operated on for severe instability, pain syndrome, neurological deficit in the period from 01/01/2014 to 09/30/2022. To assess the neurological status and patients' condition the Frankel and Karnofsky scales were used on the day of admission and discharge of the patients from the hospital. Pain intensity was assessed using a visual analog pain scale (VAS). To assess instability in the affected spinal motion segment the SINS scale was used. All patients underwent palliative surgical treatment in the amount of occipitospondylodesis with a biopsy of the neoplasm from the posterior approach.

Results. The average age of patients was 60 [44; 66] years. All patients had a marked pain syndrome prior to the surgery. The average pain intensity according to the visual analog pain scale was 8 points. In the preoperative period, 6 (85 %) patients on the Frankel scale were assigned to group E, 1 (14 %) – to group C. In 6 (85 %) patients there was no dynamics in the neurological status following the surgery, however according to the Karnofsky scale there was an improvement up to 10 points due to the regression of the pain syndrome down to 1 point on the visual analog scale. Hemiparesis developed in 1 (14 %) patient due to malposition of the laminar hook in the postoperative period. The average duration of surgical interventions made up 337.5 [315; 345] min, the average intraoperative blood loss made up 300 [300; 800] ml. In 6 out of 7 patients (85 %) there was no neurological status dynamics after the surgery, and according to the Karnofsky scale an improvement up to 10 points was noted due to regression of the pain syndrome to an average value of 1 [1; 2] VAS score.

Conclusion. The obtained results indicate the clinical application possibilities of minimally traumatic surgical technologies for the treatment of craniovertebral zone metastatic tumors.

Keywords: metastatic tumors, craniovertebral area, surgical treatment

For citation: Kit O. I., Zakondyrin D. E., Rostorguev E. E., Rostorguev V. E., Maslov A. A. Experience in surgical treatment of vertebral metastatic tumors of craniovertebral localization. South Russian Journal of Cancer. 2023; 4(3):6-11. <https://doi.org/10.37748/2686-9039-2023-4-3-1>, <https://elibrary.ru/ysuvmk>

For correspondence: Dmitry E. Zakondyrin – Cand. Sci. (Med.), MD, neurosurgeon, Moscow State Medical and Dental University named after A. I. Evdokimov, Moscow, Russian Federation.

Address: 20/1 Delegatskaya str., Moscow 127473, Russian Federation

E-mail: russiandoctor@mail.ru

ORCID: <https://orcid.org/0000-0002-0925-415X>

Compliance with ethical standards: The ethical principles presented by the World Medical Association Declaration of Helsinki, 1964, ed. 2013, were observed in the work. The study was approved by the Committee on Biomedical Ethics at the National Medical Research Centre for Oncology (extract from the protocol of the meeting No. 118 dated 06/02/2022). Informed consent was received from all participants of the study.

Funding: this work was not funded.

Conflict of interest: the authors declare that there are no obvious and potential conflicts of interest associated with the publication of this article.

The article was submitted 21.10.2022; approved after reviewing 05.07.2023; accepted for publication 14.09.2023.

© Kit O. I., Zakondyrin D. E., Rostorguev E. E., Rostorguev V. E., Maslov A. A., 2023

ОПЫТ ХИРУРГИЧЕСКОГО ЛЕЧЕНИЯ МЕТАСТАТИЧЕСКИХ ОПУХОЛЕЙ ПОЗВОНКОВ КРАНИОВЕРТЕБРАЛЬНОЙ ЛОКАЛИЗАЦИИ

О. И. Кит¹, Д. Е. Закондырин^{2✉}, Э. Е. Росторгуев¹, В. Э. Росторгуев³, А. А. Маслов³

1. НМИЦ онкологии, г. Ростов-на-Дону, Российская Федерация

2. МГМСУ им. А. И. Евдокимова, г. Москва, Российская Федерация

3. РостГМУ, г. Ростов-на-Дону, Российская Федерация

✉ russiandoctor@mail.ru

РЕЗЮМЕ

Цель исследования. Разработка методики хирургического лечения пациентов с метастатическим поражением краниовертебральной области.

Пациенты и методы. В исследование включено 7 больных с метастатическим поражением краниовертебральной области, оперированных по поводу выраженной нестабильности, болевого синдрома, неврологического дефицита в период с 01.01.2014 по 30.09.2022 гг. Для оценки неврологического статуса и состояния пациентов использовали шкалы Frankel и Karnofsky в день поступления и выписки пациентов из стационара. Интенсивность болевого синдрома оценивали по визуально аналоговой шкале боли (ВАШ). Для оценки нестабильности в пораженном позвоночно-двигательном сегменте пользовались шкалой SINS. Всем пациентам выполнено паллиативное хирургическое лечение в объеме окципитоспондилодеза с биопсией новообразования из заднего доступа.

Результаты. Средний возраст больных составил 60 [44; 66] лет. У всех пациентов до операции отмечался выраженный болевой синдром, средняя интенсивность боли по визуально аналоговой шкале боли составляла 8 баллов. В предоперационном периоде 6 (85 %) больных по шкале Frankel отнесены к группе E, 1 (14 %) – к группе C. После операции у 6 (85 %) больных динамика неврологического статуса отсутствовала, однако по шкале Karnofsky отмечалось улучшение до 10 баллов вследствие регресса болевого синдрома до 1 балла по визуально аналоговой шкале боли. У 1 (14 %) больного вследствие мальпозиции ламинарного крючка в послеоперационном периоде развился гемипарез. Средняя продолжительность выполненных оперативных вмешательств составила 337,5 [315; 345] мин, средняя интраоперационная кровопотеря – 300 [300; 800] мл. У 6 из 7 больных (85 %) динамика неврологического статуса после операции отсутствовала, а по шкале Karnofsky отмечалось улучшение до 10 баллов вследствие регресса болевого синдрома до среднего значения 1 [1; 2] балл по ВАШ.

Заключение. Полученные результаты свидетельствуют о возможностях клинического применения минимальных по травматичности технологий в хирургическом лечении метастатических опухолей краниовертебральной зоны.

Ключевые слова: метастатические опухоли, краниовертебральная область, хирургическое лечение

Для цитирования: Кит О. И., Закондырин Д. Е., Росторгуев Э. Е., Росторгуев В. Э., Маслов А. А. Опыт хирургического лечения метастатических опухолей позвонков краниовертебральной локализации. Южно-Российский онкологический журнал. 2023; 4(3): 6-11. <https://doi.org/10.37748/2686-9039-2023-4-3-1>, <https://elibrary.ru/ysuvmk>

Для корреспонденции: Закондырин Дмитрий Евгеньевич – к.м.н., врач-нейрохирург, ФГБУ ВО «МГМСУ им. А. И. Евдокимова» Минздрава России, г. Москва, Российская Федерация.

Адрес: 127473, Российская Федерация, г. Москва, ул. Делегатская, д. 20, стр. 1

E-mail: russiandoctor@mail.ru

ORCID: <https://orcid.org/0000-0002-0925-415X>

Соблюдение этических стандартов: в работе соблюдались этические принципы, предьявляемые Хельсинкской декларацией Всемирной медицинской ассоциации (World Medical Association Declaration of Helsinki, 1964, ред. 2013). Исследование одобрено Комитетом по биомедицинской этике при ФГБУ «НМИЦ онкологии» Минздрава России (выписка из протокола заседания № 118 от 02.06.2022 г.). Информированное согласие получено от всех участников исследования.

Финансирование: финансирование данной работы не проводилось.

Конфликт интересов: все авторы заявляют об отсутствии явных и потенциальных конфликтов интересов, связанных с публикацией настоящей статьи.

Статья поступила в редакцию 21.10.2022; одобрена после рецензирования 05.07.2023; принята к публикации 14.09.2023.

INTRODUCTION

Metastatic lesion of the upper cervical segments of the vertebral column occurs in no more than 0.5–1 % of cases. Due to the low frequency of lesions of the upper cervical vertebrae, most studies in the available literature are represented by small series of patients. The body of the second cervical vertebra is most often affected due to its size and abundant blood supply. The main problem of this category of patients is spinal instability, which, in addition to severe pain syndrome (in 90 % of patients), can manifest symptoms of compression of the upper spinal cord such as tetraparesis (in 0–20 % of patients), and with the development of ascending edema, even respiratory arrest and death [1; 2]. Thus, the fixation of the spine comes to the fore in the surgery of metastatic lesions of the craniovertebral region. External fixation methods (collar, Halo device) are inconvenient and can cause various complications with prolonged use in an average of 40 % of patients. And no convincing data on their effectiveness has been obtained [3]. Internal fixation methods are preferred.

According to the literature, there are several types of surgical strategies. The first and least radical option involves the use of occipitospondylodesis from the posterior access without resection of the tumor [3; 4]. The advantage of posterior access is explained by the peculiarities of the axial load distribution in the craniovertebral region, where 64 % of it falls on the posterior structures, and not on the anterior ones as in the lumbar spine. The use of occipital plates with bicortical screws and screws for

lateral masses are the methods of choice due to the high fatigue strength and torsion resistance of the structure.

The second variant of surgical tactics implies the addition of posterior fixation by vertebroplasty with transpedicular access [5], less often with transoral access [6].

The third and most radical variant of the tactic, in addition to fixation from the posterior access, implies intra-tumor resection of the neoplasm through a retropharyngeal [7; 8] and even a transmandibular [9] approach. Thus, the problem of choosing the optimal tactics in the surgical treatment of metastatic spinal tumors, including craniovertebral localization, still remains insufficiently developed.

The purpose of the study: to develop a technique for surgical treatment of patients with metastatic lesions of the craniovertebral region.

PATIENTS AND METHODS

The study included 7 patients with craniovertebral lesion out of 145 patients operated on for metastatic tumors of the vertebrae in the period from 01/01/2014 to 06/30/2022 in the Department of Neuro-Oncology of the National Medical Research Center for Oncology and the Department of Neurosurgery of the Moscow State University of Medicine and Dentistry named after A. I. Evdokimov.

To assess the neurological status and condition of patients, the Frankel and Karnofsky scales were used on the day of admission and discharge of the patient from the hospital. The intensity of the pain syndrome was assessed by a visually analog pain

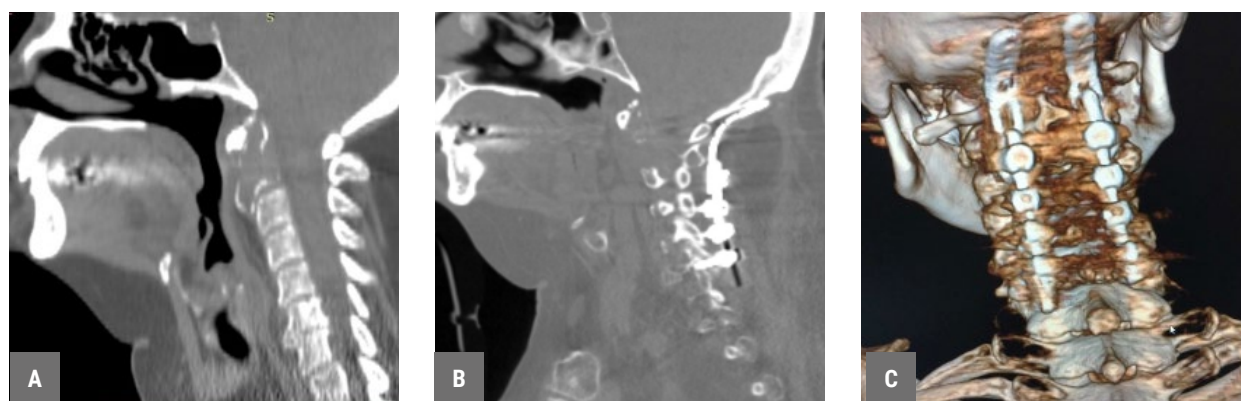


Fig. 1. Occipitospondylodesis in patient No. 3. A – computed tomography data before surgery. B, C – computed tomography data after the surgery.

scale (VAS). The SINS scale was used to assess instability in the affected vertebral-motor segment.

All patients underwent palliative surgical treatment in the volume of occipitospondylodesis with a biopsy of the neoplasm from the posterior access. Occipitospondylodesis was performed using a design consisting of occipital plates and neck screws inserted into the lateral masses, or laminar hooks (depending on surgeon's choice) (Fig. 1).

All the necessary patient data were recorded in the Microsoft Excel electronic database, after which the data was analyzed using the Statistica 7.0 program. For each group of indicators, the type of data distribution was determined (histograms were constructed according to the Kolmogorov-Smirnov agreement criterion). When the distribution differs from the normal one, median values, 1st and 3rd quartiles (Me [Q1; Q3]) were used for the description.

RESEARCH RESULTS

The study group of patients was analyzed according to such signs as: gender, age, histological type of primary tumor, localization of metastatic lesion, indicators on the Frankel, Karnofsky, VAS, SINS scales (Table 1).

The average age of the patients was 60 [44; 66] years. All patients had anterior and anterolateral localization of the neoplasm with a predominant lesion of the vertebral bodies, 2 (28 %) patients had

unilateral sprouting of the vertebral artery tumor. In 6 (85 %) patients, the degree of epidural compression corresponded to grade 1, in 1 (14 %) patient – grade 3 (due to pathological dislocation of the vertebra). The average score on the SINS scale among all patients on this scale was 8.5 [7; 9]. All patients had significant pain syndrome before surgery with the average pain intensity scores according to VAS of 8 [7; 8].

Concomitant visceral metastases were detected in 2 (28 %) patients, metastases to other bones – in 2 (28 %) patients, metastatic lesions of the liver, lungs, pelvic bones and spinal column were simultaneously diagnosed in 1 patient.

The average duration of surgical interventions performed was 337.5 [315; 345] minutes, the average intraoperative blood loss was 300 [300; 800] ml. Intraoperative complication in the form of a laminar hook malposition with spinal cord compression and the development of hemiparesis in the early postoperative period was noted in 1 patient.

The dynamics of neurological disorders on the Frankel scale and the functional status of the patient on the Karnofsky scale after surgical stabilization were analyzed in a group of patients. In 6 out of 7 patients (85 %), there was no dynamics of neurological status after surgery, and according to the Karnofsky scale, an improvement of up to 10 points was noted due to the regression of pain syndrome to an average value of 1 [1; 2] point according to VAS.

Table 1. Operated patients' characteristics

Patient	Age, years	Sex	Histology	Tumor localization	By Frankel	Scores by Karnofsky	VAS scores	SINS
Scores	66	F	Carcinoma WAD	C1-C2	E	70	7	11
2	67	M	Carcinoma WAD	C1-C2	C	50	8	9
3	44	F	Renal clear cell carcinoma	C2	E	70	8	7
4	37	M	Renal clear cell carcinoma	C1	E	70	7	7
5	59	F	Renal clear cell carcinoma	C2	E	50	10	8
6	61	M	Lung adenocarcinoma	C2-C3	E	60	8	9
7	60	M	Carcinoma WAD	C2	E	70	7	7

Note: WAD stands for: without additional details.

DISCUSSION

The purpose of surgical intervention in metastatic lesions of craniovertebral localization cannot be radical removal of the tumor. Even block resection is effective only with respect to local control of metastasis, provided it is performed within healthy tissues, but it is unable to prevent the progression of metastatic lesion in general [12]. In our opinion, intra-tumor cytorreduction of secondary neoplasm at the C1-C2 levels can be surgically extremely challenging, according to the data of literature sources (Table 2).

The analysis of publications shows that the addition of posterior fixation in case of C1-C2 segment damage by intra-tumor cytorreduction significantly lengthens the duration of surgery, significantly increases intraoperative blood loss and surgical risks, with similar results of the degree of regression of pain syndrome in the immediate and long-term post-operative period.

The benefits of surgical decompression in the developed phenomena of pronounced epidural compression of the spinal cord by a tumor at first glance seems obvious. However, Uei H. et al. [13] when choosing the volume of decompression, consider the leading factor not to be the degree of epidural compression of the spinal cord, but the severity of limb paresis and recommend the use of decompression with a degree of paresis D2 or more instead. Uei H. et al. [13] believe that there is no direct correlation between the severity of paresis and the degree of epidural compression. Uei H. et al. and other authors report the advan-

tages of stabilization without decompression over decompression-stabilizing interventions in patients with metastatic vertebral lesion, even with 2–3 degrees of epidural compression without neurological deficiency [13; 14].

In this study, it was noted that in patients, the manifestation and clinical picture of the disease caused by motor deficiency (Frankel group C) was only in 1 (17 %) of the patient, in the remaining patients there was no violation of the transverse conduction function of the spinal cord at the levels of C1-C2 segments. An MRI picture of marked epidural compression was also presented only in one case, however in another patient. Thus, there were no indications for decompression of the spinal canal in the group of patients presented by us.

Taking into account the topographic and anatomical features of the craniovertebral region, the high risks of developing instability of the craniospinal zone, accompanied by a intense pain with its metastatic lesion, the use of isolated spine stabilization technology seems to be the most favourable in the treatment of this category of patients. This is indirectly confirmed by the fact that most of the available publications on the topic of surgical treatment of metastatic lesions of the craniovertebral region describe this technology [3-6].

CONCLUSION

The data obtained by us indicate clinically satisfactory results on minimal traumatic technologies utilized in the scenario of craniovertebral zone metastatic lesions surgical treatment.

Table 2. Literature data on various types of surgical interventions performed in patients with metastatic lesions of the craniovertebral region

Intervention type	Credits	Number of patients	Procedure duration (min)	Blood loss (ml)	Complication frequency	Pain regression according to VAS
OSD*	Rustagi T. et al., 2019 [3]	39	235.0 ± 51.9	364.8 ± 252.1	8 %	From 8.3 ± 1.5 to 1.0 ± 1.1 ($p < 0.001$)
OSD+VP*	Wu X. et al., 2018 [5]	10	182 (120–255)	450 (250–850)	10 %	From 8.2 ± 0.4 to 2.3 ± 0.2 ($p < 0.001$)
OSD+TR*	Wu X. et al., 2016 [7]	15	252 (150–300)	1240 (760–2200)	27 %	From 7.86 ± 1.72 to 2.13 ± 1.40 ($p < 0.01$)

Note: OSD stands for occipitospondylodesis, OSD+VP is for combination of occipitospondylodesis and vertebroplasty, OSD+TR is for combination of occipitospondylodesis and tumor resection from retropharyngeal/posterior access.

References

1. Kit OI, Zakondyrin DE, Rostorguev EE, Yundin SV. Specifics of Epidural Compression Syndrome Surgery in Patients with Spinal Malignancy. *Creative surgery and oncology*. 2022;12(1):21–27. (In Russ.).
<https://doi.org/10.24060/2076-3093-2022-12-1-21-27>, EDN: RVNZJH
2. O'Sullivan MD, Lyons F, Morris S, Synnott K, Munigangaiah S, Devitt A. Metastasis Affecting Craniocervical Junction: Current Concepts and an Update on Surgical Management. *Global Spine J*. 2018 Dec;8(8):866–871.
<https://doi.org/10.1177/2192568218762379>
3. Rustagi T, Mashaly H, Mendel E. Posterior occiput-cervical fixation for metastasis to upper cervical spine. *J Craniovertebr Junction Spine*. 2019;10(2):119–126. https://doi.org/10.4103/jcvjs.JCVJS_29_19
4. Thirunavu V, Dahdaleh NS. Management of Atlantoaxial Instability Due to a Pathological Fracture of the Axis. *Cureus*. 2020 Jul 1;12(7):e8951. <https://doi.org/10.7759/cureus.8951>
5. Wu X, Tan M, Qi Y, Yi P, Yang F, Tang X, et al. Posterior decompression and occipitocervical fixation followed by intraoperative vertebroplasty for metastatic involvement of the axis. *BMC Musculoskelet Disord*. 2018 Jan 11;19(1):11.
<https://doi.org/10.1186/s12891-018-1928-7>
6. Kim KM, Yoon JH, Kwon JW, Gwak HS. Transoral Vertebroplasty for Osteolytic C2 Metastasis: Report of 2 Cases. *Nerve*. 2019 Apr 30;5(1):22–25. <https://doi.org/10.21129/nerve.2019.5.1.22>
7. Wu X, Ye Z, Pu F, Chen S, Wang B, Zhang Z, et al. Palliative Surgery in Treating Painful Metastases of the Upper Cervical Spine: Case Report and Review of the Literature. *Medicine (Baltimore)*. 2016 May;95(18):e3558.
<https://doi.org/10.1097/MD.0000000000003558>
8. Viola Á, Kozma I, Süvegh D. Surgery for craniocervical junction pathologies: minimally invasive anterior submandibular retropharyngeal key-hole approach. *BMC Surg*. 2021 Apr 19;21(1):199. <https://doi.org/10.1186/s12893-021-01198-z>
9. Logroscino CA, Casula S, Rigante M, Almadori G. Transmandible approach for the treatment of upper cervical spine metastatic tumors. *Orthopedics*. 2004 Oct;27(10):1100–1103. <https://doi.org/10.3928/0147-7447-20041001-22>
10. Ohashi M, Hirano T, Watanabe K, Hasegawa K, Ito T, Katsumi K, et al. En Bloc Spondylectomy for Spinal Metastases: Detailed Oncological Outcomes at a Minimum of 2 Years after Surgery. *Asian Spine J*. 2019 Apr;13(2):296–304.
<https://doi.org/10.31616/asj.2018.0145>
11. Uei H, Tokuhashi Y, Maseda M, Nakahashi M, Sawada H, Nakayama E, et al. Comparison between minimally invasive spine stabilization with and without posterior decompression for the management of spinal metastases: a retrospective cohort study. *J Orthop Surg Res*. 2018 Apr 16;13(1):87. <https://doi.org/10.1186/s13018-018-0777-2>
12. Jung JM, Chung CK, Kim CH, Yang SH. Minimally Invasive Surgery without Decompression for Hepatocellular Carcinoma Spinal Metastasis with Epidural Spinal Cord Compression Grade 2. *J Korean Neurosurg Soc*. 2019 Jul;62(4):467–475.
<https://doi.org/10.3340/jkns.2018.0199>

Information about authors:

Oleg I. Kit – RAS academician, Dr. Sci. (Med.), professor, CEO, National Medical Research Centre for Oncology, Rostov-on-Don, Russian Federation. ORCID: <https://orcid.org/0000-0003-3061-6108>, SPIN: 1728-0329, AuthorID: 343182, ResearcherID: U-2241-2017, Scopus Author ID: 55994103100

Dmitry E. Zakondyrin ✉ – Cand. Sci. (Med.), MD, neurosurgeon, Moscow State Medical and Dental University named after A. I. Evdokimov, Moscow, Russian Federation. ORCID: <https://orcid.org/0000-0002-0925-415X>

Eduard E. Rostorguev – Dr. Sci. (Med.), chief of neuro-oncological department, National Medical Research Centre for Oncology, Rostov-on-Don, Russian Federation. ORCID: <https://orcid.org/0000-0003-2937-0470>, SPIN: 8487-9157, AuthorID: 794808, Scopus Author ID: 57196005138

Vladimir E. Rostorguev – PhD student, department of traumatology and orthopedics, physical therapy and sports medicine, MD, orthopedic traumatologist, Rostov State Medical University, Rostov-on-Don, Russian Federation.

Aleksandr A. Maslov – 4th year medical student, Rostov State Medical University, Rostov-on-Don, Russian Federation.

Contribution of the authors:

Kit O. I. – research design development, article text editing, results analysis;

Zakondyrin D. E. – research design development, analysis of the obtained data, writing the manuscript;

Rostorguev E. E. – research design development, gathering the clinical material, interpretation of the results;

Rostorguev V. E. – review of publications on the topic of the article; analysis of the collected data;

Maslov A. A. – review of publications on the topic of the article; analysis of the collected data.