South Russian Journal of Cancer. 2025. Vol. 6, No. 3. P. 35-44
https://doi.org/10.37748/2686-9039-2025-6-3-4
https://elibrary.ru/ilqrhx
ORIGINAL ARTICLE

CC BY 4.0

Preliminary Results of Two-Stage Radiosurgery for Brain Metastases

Lesnoy M. N.✉, Sakun P. G., Voshedskiy V. I., Rozenko L. Ya., Vlasov S. G., Kazmenkova E. M., Babasinov A. A.

National Medical Research Centre for Oncology, Rostov-on-Don, Russian Federation
✉ mx.lesnoy@gmail.com

ABSTRACT

Purpose of the study. To perform a preliminary assessment of local control after two-stage staged radiosurgery in patients with metastatic brain lesions.

Patients and methods. For staged radiosurgery, large lesions measuring ≥ 3 cm in the largest dimension were selected. The regimen consisted of delivering 12 Gy in a single fraction at the first stage and 14 Gy in a single fraction at the second stage, with a 14-day interval between the stages. If additional smaller lesions were present, they were irradiated simultaneously using the standard SRS technique in a single fraction with a dose per fraction (DPF) of 18–24 Gy. The prospective analysis included 32 patients of both sexes aged 34 to 76 years (mean age 57 ± 3.3 years) with brain metastatic lesions ≥ 3 cm in the largest dimension, or located in close proximity to critical brain structures, who underwent a two-stage course of staged radiosurgery at the National Medical Research Centre for Oncology.

Results. The evaluation of target lesion volumes was based on brain MRI performed before treatment, prior to the second stage, and one month after completion of treatment. At the one-month follow-up after the treatment course, local control was achieved in the vast majority of clinical cases. Sixteen lesions demonstrated a volume reduction of more than 70 % from baseline, eleven showed a reduction of more than 50 %, eight lesions exhibited a decrease of less than 50 %, and one lesion demonstrated a negative response.

Conclusion. Two-stage staged radiosurgery for brain metastases demonstrated satisfactory local control in patients with various primary tumor sites. The positive dynamics observed at this stage suggest the potential for favorable long-term outcomes.

Keywords: metastatic brain lesion, radiation therapy, stereotactic radiosurgery, staged radiosurgery

For citation: Lesnoy M. N., Sakun P. G., Voshedskiy V. I., Rozenko L. Ya., Vlasov S. G., Kazmenkova E. M., Babasinov A. A. Preliminary Results of Two-Stage Radiosurgery for Brain Metastases. South Russian Journal of Cancer. 2025; 6(3): 35-44. https://doi.org/10.37748/2686-9039-2025-6-3-4, https://elibrary.ru/ilqrhx

For correspondence: Maksim N. Lesnoy – MD, PhD student, National Medical Research Centre for Oncology, Rostov-on-Don, Russian Federation
Address: 63 14 line str., Rostov-on-Don 344037, Russian Federation
E-mail: mx.lesnoy@gmail.com
ORCID: https://orcid.org/0009-0009-6084-7995
SPIN: 8452-5083, AuthorID: 1288041
Scopus Author ID: 57221944604
ResearcherID: 604536320

Compliance with ethical standards: the study was carried out in compliance with the ethical principles set forth in the World Medical Association Declaration of Helsinki (1964, revised in 2013). The study protocol was approved by the Ethics Committee of the National Medical Research Centre for Oncology, Rostov-on-Don, Russian Federation (extract from meeting protocol No. 31 dated 09/14/2023). Informed consent was obtained from all study participants

Funding: the financing of this work was carried out within the framework of the dissertation research

Conflict of interest: the authors declare that there are no obvious and potential conflicts of interest associated with the publication of this article

The article was submitted 11.02.2025; approved after reviewing 18.07.2025; accepted for publication 12.08.2025

© Lesnoy M. N., Sakun P. G., Voshedskiy V. I., Rozenko L. Ya., Vlasov S. G., Kazmenkova E. M., Babasinov A. A., 2025

Южно-Российский онкологический журнал. 2025. Т. 6, № 3. С. 35-44
https://doi.org/10.37748/2686-9039-2025-6-3-4
https://elibrary.ru/ilqrhx
3.1.6. Онкология, лучевая терапия
ОРИГИНАЛЬНАЯ СТАТЬЯ

Предварительные результаты радиотерапии метастазов головного мозга методикой двухэтапной стажированной радиохирургии

М. Н. Лесной✉, П. Г. Сакун, В. И. Вошедский, Л. Я. Розенко, С. Г. Власов, Э. М. Казьменкова, А. А. Бабасинов

ФГБУ «Национальный медицинский исследовательский центр онкологии» Министерства здравоохранения Российской Федерации, г. Ростов-на-Дону, Российская Федерация
✉ mx.lesnoy@gmail.com

РЕЗЮМЕ

Цель исследования. Предварительная оценка локального контроля после двухэтапной стажированной радиохирургии пациентов с метастатическими поражениями головного мозга.
Пациенты и методы. Для облучения методикой стажированной радиохирургии выбирались крупные очаги размером ≥ 3 см в наибольшем измерении. Методика представляла из себя подведение дозы 12 Гр за 1 фракцию на первом этапе и 14 Гр за 1 фракцию на втором этапе. Перерыв между этапами составлял 14 дней. При наличии других очагов меньшего размера, их облучение производилось одновременно по стандартной методике SRS за 1 фракцию с РОД 18–24 Гр. В проспективный анализ были включены 32 пациента обоих полов в возрасте от 34 до 76 лет, средний возраст 57 ± 3,3 года, с метастатическими очагами в головном мозге размером ≥ 3 см в наибольшем измерении, либо их близком расположении к критическим структурам головного мозга, получившие курс лечения двухэтапной стажированной радиохирургией на базе ФГБУ «Национальный медицинский исследовательский центр онкологии» Министерства здравоохранения Российской Федерации.
Результаты. Оценка объема целевых очагов производилась на основании магнитно-резонансной томографии (МРТ) исследования головного мозга, проводимого пациенту до начала лечения, перед вторым этапом и через месяц после проведенного лечения. При оценке через месяц после пройденного курса лечения в подавляющем большинстве клинических ситуаций был достигнут локальный контроль. В 16 очагах было достигнуто уменьшение объема более чем на 70 % от изначального, в 11 – более чем на 50 %, 8 показали уменьшение менее чем на 50 % и в одном очаге мы зафиксировали отрицательный ответ.
Заключение. Двухэтапная стажированная радиохирургия метастазов головного мозга показала удовлетворительные результаты локального контроля пациентов с различными первичными локализациями злокачественных заболеваний. Положительная динамика, которую мы зафиксировали на данный момент, позволяет рассчитывать на благоприятные результаты в дальнейшей перспективе.

Ключевые слова: метастатическое поражение головного мозга, лучевая терапия, стереотаксическая радиохирургия, стажированная радиохирургия

Для цитирования: Лесной М. Н., Сакун П. Г., Вошедский В. И., Розенко Л. Я., Власов С. Г., Казьменкова Э. М., Бабасинов А. А. Предварительные результаты радиотерапии метастазов головного мозга методикой двухэтапной стажированной радиохирургии. Южно-Российский онкологический журнал. 2025; 6(3): 35-44. https://doi.org/10.37748/2686-9039-2025-6-3-4, https://elibrary.ru/ilqrhx

Для корреспонденции: Лесной Максим Николаевич – научный аспирант, ФГБУ «Национальный медицинский исследовательский центр онкологии» Министерства здравоохранения Российской Федерации, г. Ростов-на-Дону, Российская Федерация
Адрес: 344037, Российская Федерация, г. Ростов-на-Дону, ул. 14-я линия, д. 63
E-mail: mx.lesnoy@gmail.com
ORCID: https://orcid.org/0009-0009-6084-7995
SPIN: 8452-5083, AuthorID: 1288041
Scopus Author ID: 57221944604

Соблюдение этических стандартов: в работе соблюдались этические принципы, предъявляемые Хельсинкской декларацией Всемирной медицинской ассоциации (World Medical Association Declaration of Helsinki, 1964, ред. 2013). Исследование одобрено Комитетом по этике при ФГБУ «Национальный медицинский исследовательский центр онкологии» Министерства здравоохранения Российской Федерации (выписка из протокола заседания № 31 от 14.09.2023 г.). Информированное согласие получено от всех участников исследования

Финансирование: финансирование данной работы проводилось в рамках диссертационного исследования

Конфликт интересов: все авторы заявляют об отсутствии явных и потенциальных конфликтов интересов, связанных с публикацией настоящей статьи

Статья поступила в редакцию 11.02.2025; одобрена после рецензирования 18.07.2025; принята к публикации 12.08.2025

BACKGROUND

Brain metastases are the most common intracranial neoplasms in adults. Secondary brain lesions most frequently occur in lung cancer (40 % of cases), breast cancer (20–30 %), and melanoma (5–15 %). Other malignant tumors metastasize to the brain less often. The problem is becoming increasingly relevant, as lung and breast cancers occupy leading positions in the structure of oncological morbidity [1].

Without specialized treatment, the median survival of patients with established brain metastases (BM) is 2–3 months, while adequate therapy can increase it to 8–12 months [2–3]. Therefore, the search for new approaches to the treatment of BM remains an important task in modern oncology and neurosurgery.

Due to the characteristics of the blood-brain barrier, systemic drug therapy is of limited effectiveness; thus, local treatment modalities play a leading role in the management of brain metastases. Surgical intervention is often impractical in cases with certain metastatic sites, multiple lesions, or tumors located in functionally critical areas of the brain [4].

With advances in technology, it has become possible to deliver high doses of ionizing radiation to the pathological focus while minimizing exposure to surrounding tissues. The technique of delivering the maximum permissible total focal dose (TFD) to the target in a single fraction is known as stereotactic radiosurgery (SRS). The term was first introduced by Lars Leksell in the mid-20th century, and for a long time, the method was limited to intracranial pathologies and considered an alternative to surgery for vascular malformations and brain tumors [5].

SRS demonstrates high efficacy however, delivering large doses in a single fraction can be associated with certain risks. Special challenges arise when irradiating large brain lesions (> 3 cm in maximum dimension), lesions with extensive peritumoral edema, or those located near critical structures. Therefore, modern clinical guidelines recommend the use of various hypofractionated stereotactic radiotherapy regimens. This approach involves delivering a comparable total focal dose over 3–5 fractions, which allows for a gentler impact on surrounding structures. However, it is known that increasing the number of fractions may reduce treatment efficacy, making this issue highly relevant in current radiation oncology [6].

To address this problem, stereotactic radiosurgery techniques are being refined. In particular, it has been proposed to deliver high single doses of radiation at specific intervals. Typically, the breaks between treatment stages range from 2 to 4 weeks, depending on the number of stages and the dose delivered at each. Literature reports describe the use of two- or three-stage approaches, with variations in the single focal dose (SFD) from 10 to 15 Gy and intervals between sessions from 14 to 30 days [7].

Given the novelty of this technique and the variable nature of brain metastases, the optimal algorithm for staged radiosurgery remains undefined; therefore, research in this field remains relevant and in demand in clinical practice.

Purpose of the study: to conduct a preliminary assessment of the primary treatment effect after two-stage staged radiosurgery in patients with metastatic brain lesions.

PATIENTS AND METHODS

An analysis was performed on the treatment outcomes of 56 patients with brain metastases selected for the study. Eligible lesions were either ≥ 3 cm in maximum diameter or smaller but located in close proximity to critical brain structures (optic chiasm, optic pathways, brainstem, etc.). Patients were divided into two groups. The main group was prospectively recruited and consisted of 32 patients who underwent two-stage staged radiosurgery of the target metastatic lesions. The control group included 24 patients whose treatment efficacy was retrospectively evaluated; in accordance with clinical guidelines, they had received radiotherapy using the standard stereotactic radiotherapy technique in a hypofractionated regimen with a total focal dose of 24 Gy in 3 fractions (8 Gy per fraction for 3 consecutive days) [10]. Treatment and follow-up were carried out from July 2023 to December 2024 at the Radiotherapy Department No. 2, National Medical Research Centre for Oncology.

The mean age of patients at treatment initiation was 57 ± 3.3 years (range 34–76 years, 95 % CI = 6.7). According to the localization of the primary tumor, the groups were divided into three subgroups. In the main group: brain metastases from breast cancer – 18 patients (56.25 %), from lung cancer – 8 patients (26.8 %), from melanoma – 6 patients (18.75 %). In the control group: brain metastases from breast cancer – 13 patients (54.17 %), from lung cancer – 7 patients (29.17 %), from melanoma – 4 patients (16.67 %). In the main group, 13 patients had solitary brain lesions, 6 patients had oligometastatic disease, and 10 patients had multiple brain metastases. Similarly, in the control group: 10 patients had solitary lesions, 8 patients had oligometastatic disease, and 9 patients had multiple brain metastases.

At the time of hospitalization, all patients showed no extracranial progression of the primary disease, had a Karnofsky Performance Status score above 70 %, and had no acute or decompensated chronic or infectious diseases, as confirmed diagnostically.

All patients included in the study underwent brain MRI prior to each treatment stage and one month after treatment completion. Before each radiotherapy stage, preliminary topometric preparation was carried out, including fabrication of an individual three-layer thermoplastic immobilization mask for stereotactic radiotherapy, placement of radiopaque markers, and determination of the isocenter using an LAP Laser navigation system. Topometric computed tomography (CT) was performed using a Siemens Somatom scanner, with an effective dose per examination of 3.7 mSv. Preliminary topometric data were processed on a Singo Via virtual simulation workstation.

Treatment plans were created and calculated using the Elements and Aria systems (Varian, USA). Three-dimensional reconstructions of the target lesions were generated, and their volumes were measured on each follow-up MRI. Patient-specific quality assurance of the treatment plan was performed using the SRS MapCheck array, SunNuclear (USA). The detector positioning and resolution of this array are designed specifically for verification of SRS/SBRT plans, ensuring high-dose measurement accuracy under conditions involving small fields and non-coplanar arcs.

Irradiation was delivered using a Novalis Tx linear accelerator (Varian, USA). Dose delivery was performed with conformal arcs. Patient positioning was verified using the ExacTrac stereotactic positioning system (BrainLab, Germany).

Staged Radiosurgery Technique

For staged radiosurgery, large lesions measuring ≥ 3 cm in their greatest dimension were selected for treatment. The gross tumor volume (GTV) and clinical target volume (CTV) were defined as the volume of the target lesion visualized on brain MRI as pathological tissue with contrast enhancement. During topometric preparation, a three-layer thermoplastic immobilization mask was used. The planning target volume (PTV) was created by adding a 1 mm margin to the GTV.

The treatment protocol consisted of delivering 12 Gy in a single fraction during the first stage and 14 Gy in a single fraction during the second stage, with a 14-day interval between stages. In the presence of other, smaller lesions, these were irradiated simultaneously according to the standard SRS protocol in a single fraction with a dose of 18–24 Gy [10].

The volume of target lesions was assessed based on brain MRI performed before treatment initiation, before the second stage, and one month after completion of treatment.

Statistical Analysis

Statistical analysis was performed using the Statistica 12.0 software package on a personal computer. Student's t-test was used, with differences considered statistically significant at a probability of error-free prediction of at least 95 % ($p < 0.05$). As part of the follow-up, the current volume of metastatic lesions and the patient's clinical status were evaluated.

STUDY RESULTS

Brain MRI follow-up was successfully performed for all patients in the study group. Monitoring data on changes in the local volume of lesions at all stages of follow-up are presented in Table 1.

The mean lesion volume at baseline was 10.8 ± 1.8 cm³ in the main group and 11.6 ± 2.0 cm³ in the control group. Lesion volumes were also as-

sessed according to the primary tumor site. In the main group, the mean volume of brain metastases was 14.2 ± 2.6 cm³ for lung cancer, 11.1 ± 2.5 cm³ for breast cancer, and 10.2 ± 2.6 cm³ for melanoma. In the control group, the corresponding mean volumes were 11.6 ± 2.0 cm³, 9.5 ± 2.7 cm³, and 8.1 ± 2.4 cm³, respectively. Thus, prior to treatment, the sizes of metastatic lesions in both groups were comparable.

In the main group, evaluation was performed 14 days after the first stage of treatment using follow-up brain MRI. The mean volumes of the lesions included in the study were 9.1 ± 2.0 cm³ for lung cancer metastases, 5.4 ± 1.9 cm³ for breast cancer metastases, and 9.1 ± 2.6 cm³ for melanoma metastases. Despite the fact that only a partial radiation dose had been delivered by this stage, a statistically significant reduction in metastatic lesion size was already observed compared with baseline. The mean lesion volume at the time of assessment before the second stage was 6.7 ± 1.4 cm³ (p = 0.05), corresponding to a 38 % reduction.

The third MRI assessment was performed one month after completion of treatment for both patient groups. The mean lesion volume in the main group was 4.3 ± 0.6 cm³ (p = 0.05), compared with 6.27 ± 1.4 cm³ in the control group. Relative to baseline, this represented a 60.1 % and 35.4 % reduction, respectively. Notably, the best response to radiotherapy was observed in metastatic lesions from disseminated breast cancer. In the main group, the mean baseline volume was 11.1 ± 2.5 cm³, and one month after completion of the two-stage treatment it had decreased significantly to 2.1 ± 0.6 cm³ (p < 0.05), representing a more than fivefold reduction (77.5 %). In the control group, the mean baseline volume was 9.5 ± 2.7 cm³, and one month after radiotherapy it decreased to 5.2 ± 0.7 cm³ (a 45.3 % reduction), which was not statistically significant.

An example of lesion volume reduction in a patient who underwent staged radiosurgery is presented in Figure 1.

In the subgroup of patients with metastatic lung cancer, one month after treatment we recorded a statistically significant decrease in lesion volume to 4 ± 1.1 cm³ (p < 0.05) in the main group (a 77 % reduction from baseline) and to 7.3 ± 0.9 cm³ in the control group (a 37.7 % reduc-

Table 1. Mean volume of metastatic lesions in patients at three stages of treatment, taking into account morphological type

Primary tumor site	Number of patients		Lesion volume before treatment (cm³)		Lesion volume before the second stage (cm³)	Lesion volume one month after treatment (cm³)	
	Main group	Control group	Main group	Control group	Main group	Main group	Control group
Lung cancer	8	7	14.2 ± 2.6	11.6 ± 2.0	9.1 ± 2.0	4 ± 1.1*	7.3 ± 0.9
Breast cancer	18	13	11.1 ± 2.5*	9.5 ± 2.7	5.4 ± 1.9*	2.1 ± 0.6*	5.2 ± 0.7
Melanoma	6	4	10.2 ± 2.6	8.1 ± 2.4	9.1 ± 2.6	7.0 ± 1.1	6.3 ± 1.2
Total	32	24	10.8 ± 1.8*	9.7 ± 2.1	6.7 ± 1.4*	4.3 ± 0.6*	6.27 ± 1.4

Note: * – Statistically significant reduction compared with baseline volume (p = 0.05). The "± n" value indicates the standard error of the mean (SEM)

tion from baseline). Hypofractionated irradiation in the control group did not result in a statistically significant difference.

The smallest reduction in mean lesion volume was observed in the subgroup of patients with melanoma metastases: from 10.2 ± 2.6 cm³ at baseline to 6.3 ± 1.2 cm³ on MRI one month after treatment.

In addition to the evident clinical changes in lesion volume, we were also able to assess the reduction of peritumoral edema observed in some patients. Pronounced peritumoral edema was noted in 12 cases in the main group and 9 cases in the control group. Edema volume was assessed separately from the volume of the target lesion. The mean peritumoral edema volume before treatment was 7.53 ± 1.2 cm³ in the main group and 5.6 ± 0.7 cm³ in the control group. At the assessment before the second treatment stage, the mean peritumoral edema volume in the main group was 5.3 ± 0.6 cm³, representing a 30 % reduction from baseline. One month after treatment, peritumoral edema was no longer detectable on imaging in 3 patients from the main group. In the remaining 9 patients, the mean edema volume was 3.47 ± 0.5 cm³ (p = 0.05). In the control group, peritumoral edema was not detectable in 1 patient at the one-month follow-up. In the remaining 8 patients, the mean edema volume was 3.55 ± 0.7 cm³, corresponding to a 33 % reduction. Given the relatively small patient sample, we cannot draw definitive conclusions regarding the statistically significant impact of staged radiosurgery on peritumoral edema reduction. However, the fact that measurable edema reduction was observed as early as 14 days after the first treatment stage comparable to the results in the control group at one month suggests that this approach may represent a promising direction for further, larger-scale research.

DISCUSSION

It is well known that in the treatment of brain metastases (BM), a particular challenge is posed by large metastatic brain lesions (> 3 cm in their greatest dimension) or even smaller lesions located in close proximity to functionally critical areas of the brain (eyes, lenses, optic nerves, chiasm, optic tracts, brainstem, hippocampus) [11]. It has been established that the maximum radical dose for lesions up to 2 cm in diameter, located away from critical structures, is approximately 24 Gy. As the lesion volume increases, the volume of uninvolved brain tissue affected by the irradiation grows proportionally. Accordingly, the maximum permissible dose decreases. For lesions larger than 3 cm, the highest safe dose is around 15 Gy.

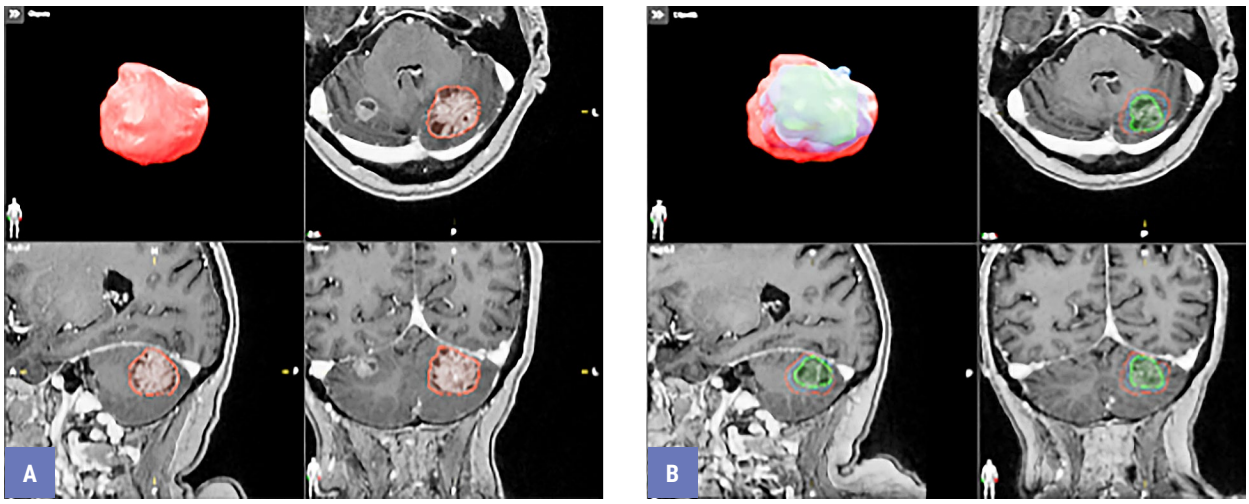

Fig. 1. Volumetric contours of a metastatic lesion in a patient with disseminated breast cancer: A) before the initiation of radiotherapy; B) one month after completion of radiotherapy

A radical reduction in the total lesion dose inevitably leads to reduced treatment efficacy and an increased risk of intracranial progression [12].

For such large lesions, hypofractionated radiotherapy can be employed. Clinical guidelines describe a regimen of 8 Gy per fraction over three fractions, thereby delivering a total dose of 24 Gy [10]. Although the final total dose remains the same as in classical radiosurgery, some evidence suggests that fractionation reduces tumoricidal efficacy. Nevertheless, this regimen remains sufficiently intensive, delivering a high total dose over a relatively short period, and therefore retains the risk of complications associated with peritumoral edema and involvement of nearby critical structures [13].

In search of a solution to this problem, ongoing work has been devoted to the development of staged stereotactic radiosurgery (stSRS), in which an equivalent radical dose for large brain metastases is delivered in multiple stages with intervals of 2–4 weeks.

Higuchi Y, et al. (2009) conducted a prospective study including 43 patients with large BM volumes (> 10 cm³, range 10–35.5 cm³). The treatment scheme consisted of 10 Gy per fraction in a radiosurgical mode, followed by a 14-day break, repeated twice for a total of three sessions. Thus, the total dose after three stages was 30 Gy. The mean tumor volume reduction was 18.8 % and 39.8 % at the time of the second and third sessions, respectively. Intracranial progression-free survival at 12 months was 80.7 %. Local control was not achieved in three cases due to recurrence, in five cases due to symptomatic peritumoral edema, and in one case due to hemorrhage. New lesions were detected in 24.8 % of patients at 6 months and in 34.2 % at 12 months [8].

Medvedeva KE, et al. (2022) analyzed the treatment of 31 BM patients who underwent two-stage stSRS using the Gamma Knife platform. The median total dose after two stages was 30 Gy (range 22–49 Gy), with an interval of up to 33 days between sessions. The median tumor volume before therapy was 10.4 cm³. MRI follow-up was performed at four time points: before the second stage, and at 3, 6, and 12 months after treatment. Follow-up data were available for 21, 14, 11, and 4 patients at each respective time point, the reduction being due to extracranial disease progression. Mean lesion volume reductions at each stage were 41.4 %, 43 %, 56.4 %, and 56.7 %. Intracranial progression was observed in two patients at the first, second, and third follow-ups. Radionecrosis was detected in two cases, at 4 and 15 months after treatment [9].

In the present study, a two-stage regimen was used: 12 Gy in a single fraction at the first stage and 14 Gy in a single fraction at the second stage, with a 14-day interval between them [8].

The choice of the dosing regimen at the stages of radiosurgery was based on the calculation of the biologically effective dose (BED) using the formula $BED = D \times (1 + d/(a/b))$ [14]. The reference point was the standard radiosurgery regimen for metastatic lesions from breast cancer measuring less than 3 cm at the largest dimension. Delivering 24 Gy to the lesion with a radiosensitivity coefficient a/b = 4.6 (for breast cancer histology) resulted in a biologically effective dose of 149.22 isoGy.

When recalculating the biologically effective dose for hypofractionated irradiation with a single dose of 8 Gy for three fractions and a total focal dose (TFD) of 24 Gy, we obtain 65.74 isoGy, which clearly demonstrates how the effectiveness of radiotherapy decreases when the dose is reduced and a hypofractionated approach is used.

Therefore, aiming to increase the iso-effectiveness of the delivered dose, a two-stage irradiation regimen with doses of 12 Gy and 14 Gy was chosen, resulting in a cumulative iso-effectiveness of 99.9 isoGy with an arithmetic cumulative TFD of 26 Gy. A lower dose is delivered at the first stage because initially we are dealing with a large lesion, which may also be surrounded by peritumoral edema and therefore requires a more sparing irradiation regimen to avoid neurocognitive impairment. By the second stage, due to the dose already delivered and the use of anti-edema therapy, the volume of the lesion and the peritumoral edema area usually decreases, making it possible to deliver a higher dose while maintaining patient safety.

Attention in this study may also be drawn to the varying responses of lesions to treatment depending on the location of the identified primary tumor and histological type. In our cohort, the best results were observed in metastatic lesions from

generalized breast cancer, where the mean volume reduction exceeded 70 % and was clinically significant. In contrast, metastatic melanoma lesions demonstrated greater radioresistance, which is characteristic of the histological structure of the tumor. We cannot draw definitive conclusions on this matter because a larger sample size would be needed for statistically reliable research. However, the preliminary results of this study suggest that in an attempt to improve the clinical effect of the proposed treatment, radiomodification could be considered.

Of note in our data is the variability in treatment response depending on the primary tumor site and histology. The best results were seen in breast cancer BM, with mean volume reductions exceeding 70 %, a clinically significant effect. By contrast, melanoma BM demonstrated greater radioresistance, consistent with known histological characteristics. Definitive conclusions are limited by the sample size, but these preliminary findings suggest that radiomodification might improve outcomes.

We also note the potential impact of stSRS on reducing peritumoral edema, which is clinically important in intracranial symptomatology and limits radiotherapy planning [13]. Our findings suggest that a lower first-stage dose may reduce pronounced peritumoral edema, creating more favorable conditions for delivering a radical dose at the second stage, thereby increasing both efficacy and safety in BM treatment.

There are also grounds to hypothesize that staging may positively affect radioresistant tumor characteristics. In melanoma BM, increased resistance to DNA double-strand breaks from radiation is well-documented [15]. With hypofractionated regimens, the marginal dose is delivered to an essentially unchanged tumor because the period for radiation effect manifestation is short, potentially explaining the lower volume reductions observed in melanoma BM in our study. In contrast, stSRS yielded better outcomes, possibly because the interstage interval allowed partial tumor pathomorphosis, reducing radioresistance.

CONCLUSION

Two-stage staged stereotactic radiosurgery for brain metastases has demonstrated satisfactory local control in patients with various primary tumor sites. Follow-up is ongoing, but the positive dynamics observed thus far support the expectation of favorable long-term results. Investigating correlations between histology and treatment response, comparing this technique to other staged radiosurgery protocols, and exploring possible clinical effects associated with stSRS remain promising areas for further research. At this stage, the achieved degree of local control with the proposed dosing and interstage interval offers a viable treatment option for large brain metastases.

References

1. The state of oncological care for the Russian population in 2021. Ed. by A. D. Kaprin, V. V. Starinsky, A. O. Shakhzadova. Moscow: P. A. Herzen MNIOI – Branch of the National Medical Research Radiological Center, 2022, 239 p. (In Russ.).
2. Voshedskii VI, Dzhenkova EA. Modified precision stereotactic radiation treatment of metastatic brain damage by non-small cell lung cancer. Issues of Oncology. 2023;69(3S):447–448. (In Russ.). EDN XIDMDW
3. Ernani V, Stinchcombe TE. Management of Brain Metastases in Non-Small-Cell Lung Cancer. J Oncol Pract. 2019 Nov; 15(11):563–570. https://doi.org/10.1200/JOP.19.00357
4. Winther RR, Hjermstad MJ, Skovlund E, Aass N, Helseth E, Kaasa S, et al. Surgery for brain metastases-impact of the extent of resection. Acta Neurochir (Wien). 2022 Oct;164(10):2773–2780. https://doi.org/10.1007/s00701-021-05104-7
5. Engel OT, Nazarenko AV. The history of stereotactic radiosurgery development and its role in the treatment of brain metastases. Head and Neck Tumors (HNT). 2015;5(1):27–35. (In Russ.). https://doi.org/10.17650/2222-1468-2015-1-27-35
6. Yan M, Zalay O, Kennedy T, Owen TE, Purzner J, Taslimi S, et al. Outcomes of Hypofractionated Stereotactic Radiotherapy for Small and Moderate-Sized Brain Metastases: A Single-Institution Analysis. Front Oncol. 2022;12:869572. https://doi.org/10.3389/fonc.2022.869572

7. Cui T, Weiner J, Danish S, Chundury A, Ohri N, Yue N, et al. Evaluation of Biological Effective Dose in Gamma Knife Staged Stereotactic Radiosurgery for Large Brain Metastases. Front Oncol. 2022;12:892139. https://doi.org/10.3389/fonc.2022.892139
8. Osinov IK, Golanov AV, Banov SM, Artemenkova AE, Kostuchenko VV, Dalechina AV. Staged radiosurgery in the managment of patients with brain metastases. Russian Journal of Neurosurgery. 2021;23(1):26–37. (In Russ.). https://doi.org/10.17650/1683-3295-2021-23-1-26-37
9. Medvedeva KE, Baulin AA, Lipilina OG, Kvashnin KM, Ilyalov SR. Two-stage interned stereotactic radiosurgery on a gamma knife in the treatment of brain metastases. Radiation and Risk (NER Bulletin). 2022;31(1):136–149. (In Russ.). https://doi.org/10.21870/0131-3878-2022-31-1-136-149, EDN: IMEWWY
10. Clinical recommendations. Secondary malignant neoplasm of the brain and meninges. 2024. (In Russ.). Available at: https://cr.minzdrav.gov.ru/preview-cr/534_3, Accessed: 07/09/2025
11. Sarmey N, Kaisman-Elbaz T, Mohammadi AM. Management Strategies for Large Brain Metastases. Front Oncol. 2022;12:827304. https://doi.org/10.3389/fonc.2022.827304
12. Crisà FM, Leocata F, Arienti VM, Picano M, Berta L, Brambilla MG, et al. Adaptive Staged-Dose Gamma Knife Radiosurgery for the Treatment of Large Brain Metastases: Report of 40 Consecutive Cases and Analysis of Literature. Neurol India. 2023;71(Supplement):S146–S152, Mar–Apr 2023. https://doi.org/10.4103/0028-3886.373643
13. Pan K, Wang B, Xu X, Liang J, Tang Y, Ma S, et al. Hypofractionated stereotactic radiotherapy for brain metastases in lung cancer patients: dose-response effect and toxicity. Discov Oncol. 2024 Jul 30;15(1):318. https://doi.org/10.1007/s12672-024-01191-x
14. Arsenyev AI, Novikov SN, Kanaev SV, Melnik YuS, Arsenyev EA, Nefedov AO, et al. Radiobiology of high-dose radiation therapy: a textbook for students in higher education and additional professional education. Saint Petersburg: N. N. Petrov National Medical Research Center of Oncology, 2022, 156 p.
15. Lambing S, Tan YP, Vasileiadou P, Holdenrieder S, Müller P, Hagen C, et al. RIG-I immunotherapy overcomes radioresistance in p53-positive malignant melanoma. J Mol Cell Biol. 2023 Jun 1;15(1):mjad001. https://doi.org/10.1093/jmcb/mjad001

Information about authors:

Maksim N. Lesnoy ✉ – MD, PhD student, National Medical Research Centre for Oncology, Rostov-on-Don, Russian Federation
ORCID: https://orcid.org/0009-0009-6084-7995, SPIN: 8452-5083, AuthorID: 1288041, Scopus Author ID: 57221944604, ResearcherID: 604536320

Pavel G. Sakun – MD, Cand. Sci. (Med.), radiation oncologist, neurosurgeon, Head of Radiotherapy Department No. 2, National Medical Research Centre for Oncology, Rostov-on-Don, Russian Federation
ORCID: https://orcid.org/0000-0001-8061-6259, SPIN: 3790-9852, AuthorID: 734600, Scopus Author ID: 56531945400

Vitalii I. Voshedskiy – MD, radiation oncologist, National Medical Research Centre for Oncology, Rostov-on-Don, Russian Federation
ORCID: https://orcid.org/0000-0003-1405-8329, SPIN: 4732-4005, AuthorID: 1032685, ResearcherID: Q-6122-2019

Lyudmila Ya. Rozenko – MD, Dr. Sci. (Med.), Professor, Radiation Oncologist, Department of Radiotherapy No. 2, National Medical Research Centre for Oncology, Rostov-on-Don, Russian Federation
ORCID: https://orcid.org/0000-0001-7032-8595, SPIN: 8879-2251, AuthorID: 421802

Stanislav G. Vlasov – MD, Cand. Sci. (Med.), Radiation Oncologist, Department of Radiotherapy No. 2, National Medical Research Centre for Oncology, Rostov-on-Don, Russian Federation
ORCID: https://orcid.org/0000-0002-4680-8991, SPIN: 3001-7426, AuthorID: 1087319, ResearcherID: AAJ-6426-2021

Evelina M. Kazmenkova – MD, Resident Doctor, National Medical Research Centre for Oncology, Rostov-on-Don, Russian Federation
ORCID: https://orcid.org/0009-0002-0871-3438

Artem A. Babasinov – MD, PhD student, National Medical Research Centre for Oncology, Rostov-on-Don, Russian Federation
ORCID: https://orcid.org/0009-0007-1634-902X, SPIN: 5443-3908, AuthorID: 1288044, ResearcherID: JFK-4065-2023

Contribution of the authors:

Lesnoy M. N. – study design, data acquisition, data analysis, manuscript writing, literature review;
Sakun P. G. – critical revision of the manuscript, final approval of the version to be published;
Voshedskiy V. I. – study design, critical revision of the manuscript, final approval of the version to be published;
Rozenko L. Ya. – critical revision of the manuscript, final approval of the version to be published;
Vlasov S. G. – literature review, data acquisition, data analysis, manuscript writing;
Kazmenkova E. M. – literature review, data acquisition, data analysis, manuscript writing;
Babasinov A. A. – literature review, data acquisition, data analysis, manuscript writing.